The Conscience of EMS
JEMS
JOURNAL OF EMERGENCY MEDICAL SERVICES ®JEMS

Patient's Elevated Airway Pressure Puzzles Providers

By Benjamin Briggs, EMT-P and John Freese, MD | 11.28.18

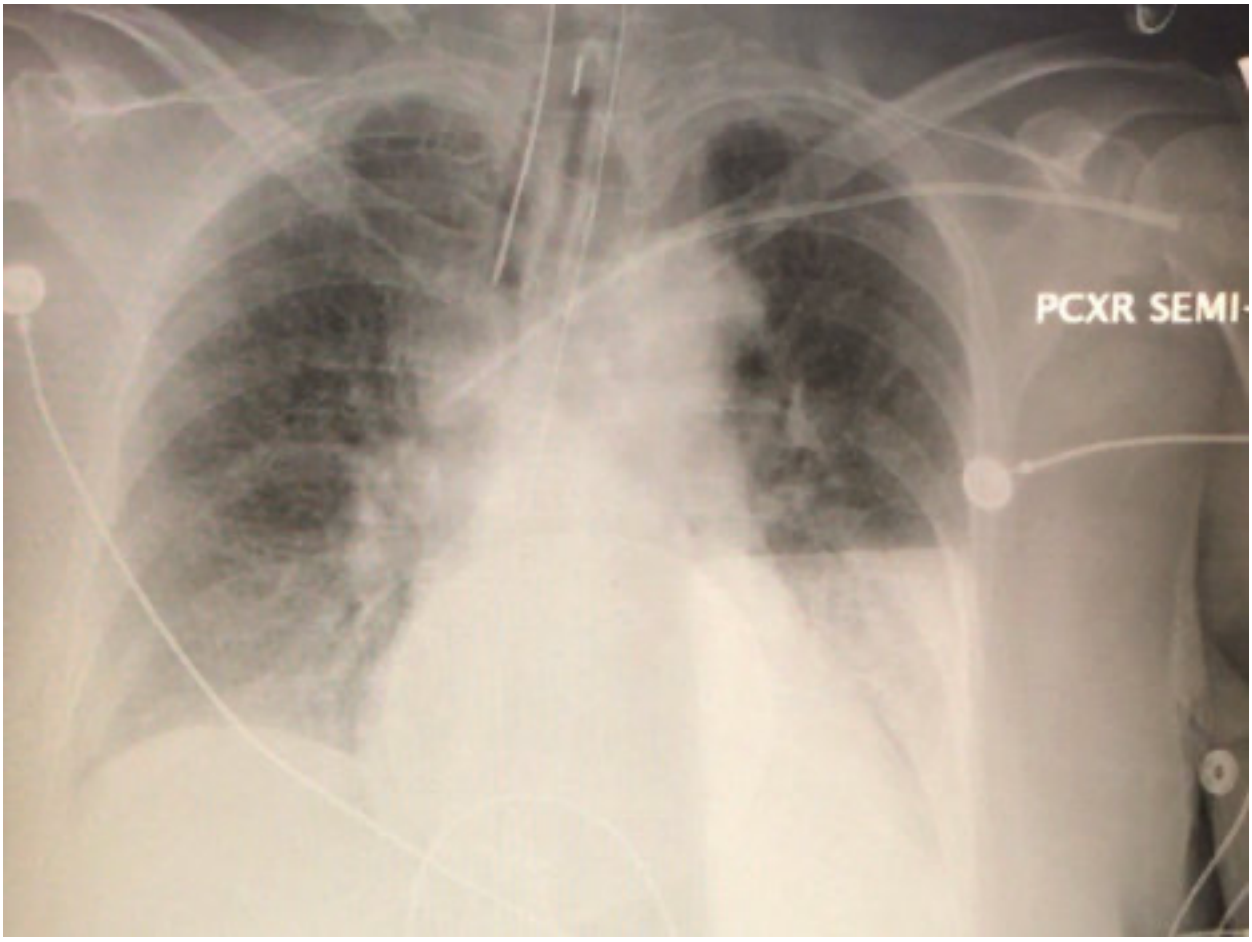

An ALS crew is dispatched to the scene of a patient reported to have altered mental status and difficulty breathing. Upon arrival, you and your partner find a middle-age woman lying on the floor in the care of first responders with visibly shallow respirations.

According to the patient's family, she was in her normal state of health and sitting in her recliner when she suddenly raised her hands into the air and began grabbing at both sides of her head. She then fell forward and was assisted to the ground by family.

Family members describe grunting respirations that began shortly thereafter and no change in her mental status from the time of the 9-1-1 call until the arrival of the paramedics. She reportedly has no medical problems, takes no medications and hasn't recently suffered any injuries.

In your initial assessment, you notice that the patient withdraws from pain, but is otherwise unresponsive (Glasgow coma scale of 6); has pale and diaphoretic skin; shallow respirations without any abnormal lung sounds; left-sided flaccidity (upper and lower extremities); and no other significant physical findings.

Your partner tells you that the patient's initial vital signs include a heart rate of 88, blood pressure of 152/92 mmHg, oxygen saturation of 42%, and shallow respirations at 36 breaths per minute.

Oxygen is immediately applied via non-rebreather mask and two peripheral IVs are established. The patient's blood glucose is measured and found to be 153 mg/dL.

The patient's oxygen saturation improves to only 88% with the non-rebreather mask, and considering her lack of protective airway reflexes, the decision is made to perform rapid sequence intubation, which is allowed under protocol for approved paramedics by system medical directors in your state.

Etomidate (30 mg) and rocuronium (100 mg) are administered for induction and neuromuscular blockade, respectively, based upon her estimated 100 kg (220 lbs.) weight.

The patient is easily intubated on the first attempt with a 7.0 mm endotracheal tube, which is secured at 23 cm at the lip. No emesis, foreign body or other obstruction was noted during direct laryngoscopy.

Tube placement is confirmed by direct visualization, auscultation and waveform capnography with an initial $EtCO_2$ value of 112 mmHg. Breath sounds are noted to be rhonchorous throughout.

Though the patient was initially somewhat difficult to ventilate with bag-valve mask ventilation, adjustment of the endotracheal tube cuff pressure seems to relieve this issue. But when you place the patient on a mechanical ventilator for transport (initial settings: volume control; rate 16/min.; FiO_2 = 100%; tidal volume = 400 mL; PEEP = 5 cmH_2O; Inspiratory:Expiratory ratio (I:E) = 1:3.2), and even following the administration of 100 mcg of fentanyl and 5 mg of midazolam for

sedation, multiple high pressure alarms occur with no change in the assessment of airway placement.

Unable to remedy the high pressure limits with adjustments in tidal volume, PEEP or I:E times, you remove the patient from the ventilator and continue bag-valve mask ventilation while en route to the ED.

Vital signs upon arrival at the hospital are noted to be a heart rate of 88, BP of 122/62 mmHg, oxygen saturation of 99%, and $EtCO_2$ of 88 mmHg. Just as the receiving physician opens the back doors and begins to inquire about the patient's present status, she becomes bradycardic and then pulseless. Tube placement is again verified as CPR is initiated, and the patient is moved immediately into the ED.

In the ED, standard resuscitative efforts are initiated and result in return of spontaneous circulation eight minutes after the patient's arrival.

As had been described in the field, the patient's airway pressures remain significantly elevated (> 40 cmH_20) when the ED ventilator was applied, despite variations in ventilator settings. Diffuse wheezes and scattered rales were also noted.

Endotracheal suction is performed with no resistance noted and only minimal sputum return. Bronchodilators are administered with little improvement noted in her airway pressures.

An arterial blood gas is performed at 15 minutes after return of spontaneous circulation and demonstrates a continued respiratory acidosis (pH: 7.02; CO_2: 87 mmHg) and an oxygen saturation of 99% (PaO_2: 196 mmHg).

A chest X-ray is read by radiology as, "No acute cardiopulmonary disease; lines and tubes in appropriate position." (See Figure 1.)

Figure 1: Patient's chest X-ray: no acute cardiopulmonary disease; lines and tubes in appropriate position

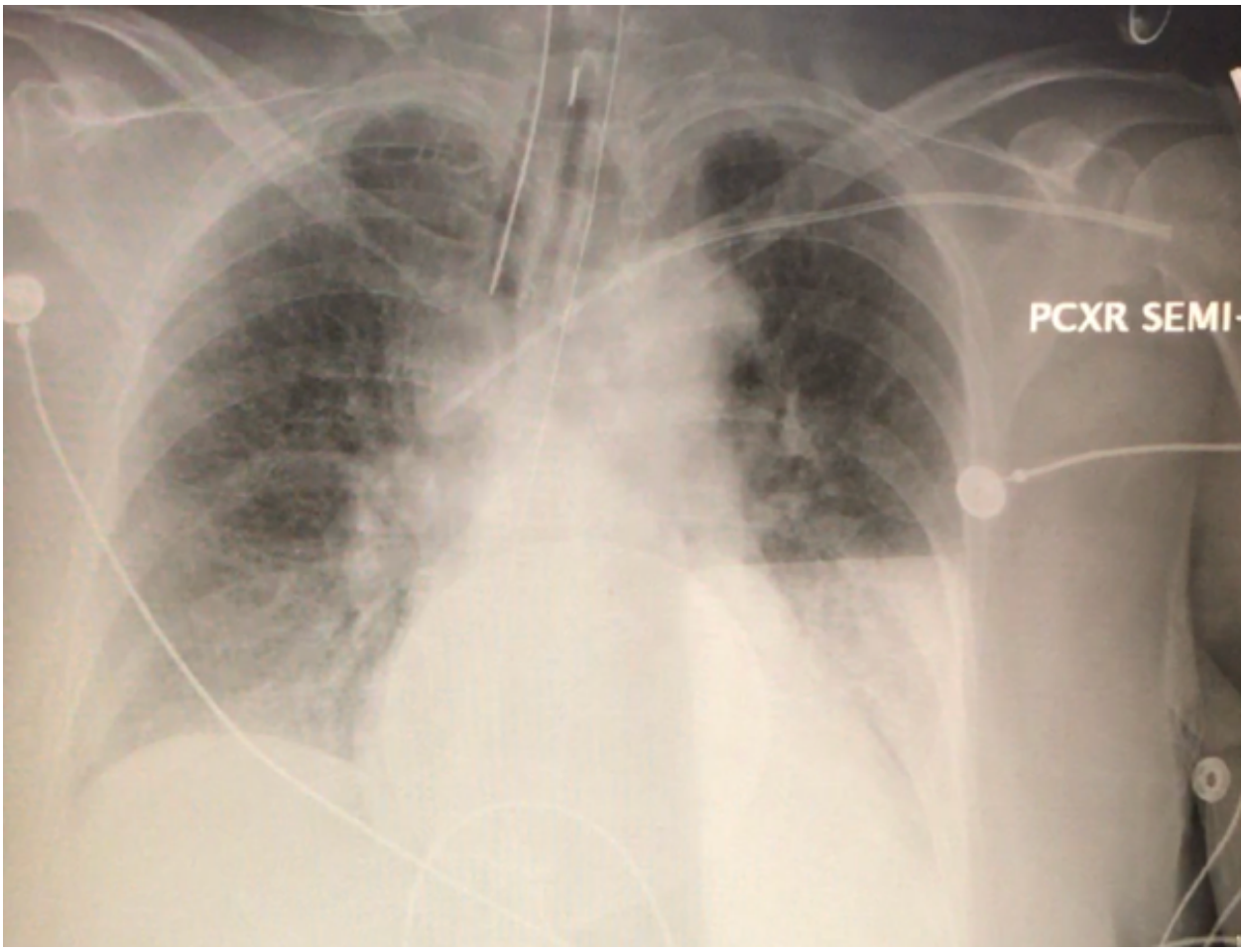

Unfortunately, without additional sedatives having been administered, the patient remains unresponsive to stimuli.

Discussion

Whether they're "sensed" through difficulty in ventilating a patient manually via a bag-valve mask or noted because of a ventilator alarm, elevated airway pressures present a risk of harm to the patient.

Many ventilators are set to not only alarm at certain airway pressures, but to alter the inspiratory flow delivered to a patient in order to avoid further elevations in airway pressure. This may result in a reduction in the tidal volume delivered to the patient and/or reduced minute ventilation, both of which may result in hypoventilation and resulting hypercapnia.

This adjustment, which ventilators often make in the setting of elevated airway pressures, is independent of the cause. But, rather than just blindly adjusting ventilator settings in an attempt to correct the problem, identifying the cause of the elevated airway pressures and—if possible—correcting it, is the prudent course. This is because, in addition to hypoventilation, continuous elevation of the patient's airway pressures can lead to barotrauma (i.e., pneumothoraces), damage at the alveolar-capillary interface (leading to non-cardiogenic pulmonary edema) and hypotension due to elevated intrathoracic pressures that reduce venous return and preload.

There are a number of possible causes of elevated airway pressures. It's sometimes useful to divide them into two groups: 1) those caused by the airway intervention; and 2) those caused by the patient themselves.

Quite simply, anything that causes a partial obstruction of the airway may result in elevated airway pressures. These include kinks in the ventilator tubing, water or other liquids within the airway (e.g., ventilator tubing, endotracheal tube), kinking of the endotracheal tube or obstruction of the endotracheal tube with foreign material.

Elevated airway pressures may also be detected with a mainstem bronchus intubation or inappropriate ventilator settings (e.g., short inspiratory time).

If the cause of the elevated airway pressures doesn't lie with the airway intervention, it may be a reflection of a problem with the patient themselves. Bronchospasm, pneumonia, pulmonary edema (including non-cardiogenic pulmonary edema, or acute respiratory distress syndrome[ARDS]), pneumothorax or even significant obesity can be reflected in elevated airway pressures.

Inadequate sedation which causes the patient to cough or "fight" the ventilator or ventilations will also generate elevated airway pressures.

Though most of us have experienced elevated airway pressures far more often when delivering manual ventilations, elevated airway pressures in the setting of ventilator use can actually help to determine whether the problem lies with "our" airway or with the patient.

To understand this, we need to briefly review the airway pressures that occur during positive pressure ventilation. As ventilation begins, the pressure within the airway will rise continuously and, at the end of inspiration, reaches the peak inspiratory pressure (PIP).

As exhalation begins, the airway pressure will immediately decline. If we pause or stop exhalation immediately thereafter, we can measure the plateau pressure. Plateau pressure is a reflection of the compliance of (i.e., resistance within) the lung, specifically the alveoli. And the difference between the PIP and plateau pressure is a reflection of resistance within the upper airway. This curve is shown in Figure 2.

Figure 2: Peak-to-plateau pressure difference (double-headed arrow) is obtained after an inspiratory hold by comparing the peak pressure and the measured plateau pressure.
Source: Rotta AT, Steinhorn DM. Conventional mechanical ventilation in pediatrics. J Pediatr

(Rio J). *2007 May;83(2 Suppl):S100–S108.*

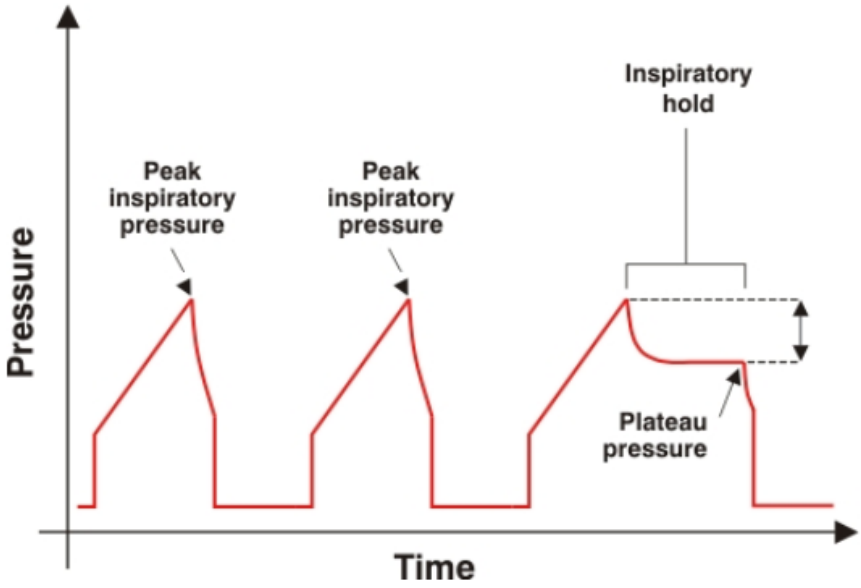

For a normal patient, PIP is typically < 40 cmH_2O, plateau pressure is < 30 cmH_2O and, therefore, resistance in the upper airway is approximately 10 cmH_2O.

Elevated airway pressures with an elevated PIP but a normal plateau pressure are suggestive of problems with the airway itself (e.g., endotracheal tube, ventilator tubing, etc.).

The normal plateau pressure in those cases reflects the "normal" status of the patient and their lungs. In such cases, the airway resistance (R_{aw}, which equals PIP minus plateau pressure) is typically > 10 cmH_2O.

Elevated airway pressures in patients with both an elevated PIP and an elevated plateau pressure are suggestive of problems with the patient (e.g., bronchospasm, pneumothorax, etc.). R_{aw} in these cases will be < 5 cmH_2O.

Figure 3: Plateau pressure and peak inspiratory pressure as it relates to airway resistance vs. lung compliance

Source: Chang DW: Clinical application of mechanical ventilation*. Cengage Learning: Clifton Park, N.Y., 2014.*

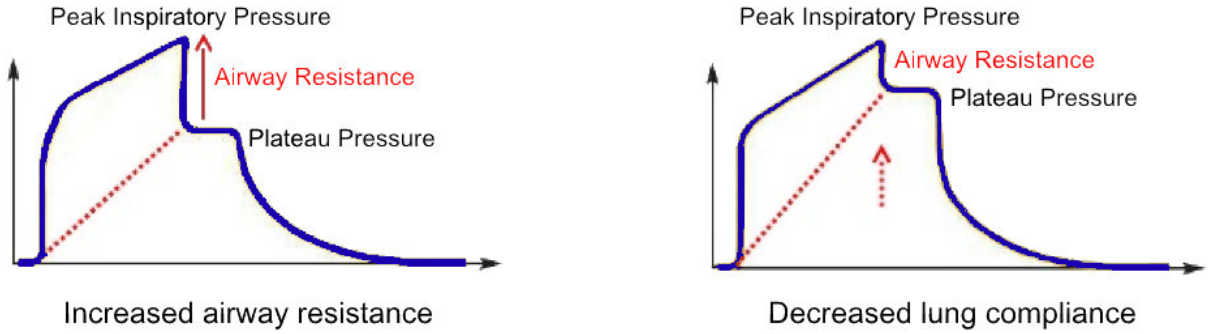

Whether you use a ventilator capable of providing you with plateau pressures (i.e., inspiratory pause) or not, you can still attempt to troubleshoot various points along the airway in an attempt to identify and remedy the cause of the elevated airway pressures.

If the patient is on a ventilator, immediately remove them from the ventilator circuit and provide manual ventilation.

If the patient is now easy to ventilate without perceived elevated airway pressures, the problem almost certainly lies in the ventilator and/or its circuit.

Manual ventilation should continue until the problem is corrected.

If the patient's airway pressures are still elevated after removing them from the ventilator (i.e., they are "hard to bag"), ensure that the endotracheal tube is not the problem. Check to see if the depth is proper (approximately 3 times tube size in cm) or potentially too deep, reflecting a mainstem bronchus intubation.

Also check to see if the endotracheal tube is kinked or obstructed. This is often easily determined by passing a soft suction catheter to a depth greater than the length of the tube to assess for resistance.

If the problem lies beyond the endotracheal tube, does reassessment of the patient provide any insight as to the cause? Is there wheezing to suggest bronchospasm? Absent or diminished breath sounds unilaterally may suggest a previously unrecognized mainstem bronchus intubation or a pneumothorax.

Are diffuse rales (suggesting pulmonary edema or ARDS) or localized rales/rhonchi (suggesting pneumonia or atelectasis) present? Is the patient actively coughing or "fighting the vent," suggesting a need for further sedation? Is the abdomen significantly distended, suggesting decreased lung compliance due to abdominal resistance?

Once you've identified the cause, it then becomes easier to proceed with correcting the problem or treating the underlying pathophysiology.

Case Conclusion

In this case, the patient's high airway pressures continued even after she was removed from the ventilator, as evidenced by the difficulty with manual ventilation. Thus, the problem wasn't with the ventilator or its tubing.

The endotracheal tube was properly placed, as evidenced by the presence of bilateral breath sounds, its depth and placement as visualized on chest X-ray. And the tube didn't appear to be kinked or otherwise obstructed based upon the ability to easily pass an endotracheal suction catheter.

Given the wheezing heard on auscultation—and even though the patient had no history of pulmonary disease—bronchodilators were administered but failed to improve the airway pressures.

No other abnormal lung sounds were appreciated, her chest X-ray failed to demonstrate any other pathology, and she was unresponsive, so inadequate sedation didn't seem to be of concern.

The patient then underwent a CT scan of her chest to exclude a pulmonary embolus or other pathology, and it was through this procedure that the cause of her airway obstruction was found: Although placed at a proper depth, the beveled end of the endotracheal tube was aligned with the wall of the trachea and the only means of ventilating the patient was the "Murphy eye." (See Figure 4.)

Figure 4: Beveled end of endotracheal tube aligned with the wall of the trachea.

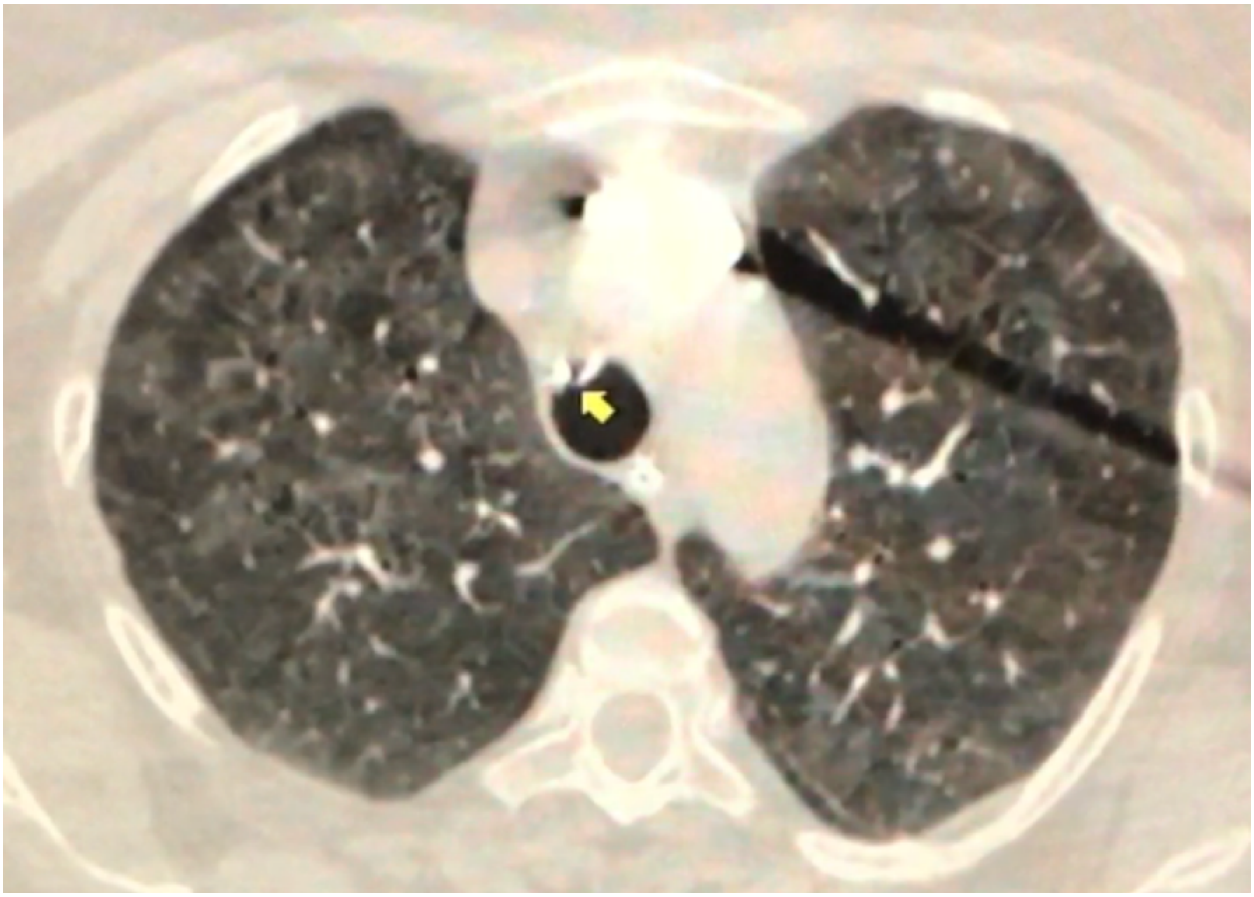

Following review of this CT, the patient's endotracheal tube was maintained at its previously placed depth and rotated 90 degrees. The patient's airway pressures immediately returned to normal. Within one hour, her hypercapnia was corrected and she was awake and following commands.

This case represents a unique instance of iatrogenic (i.e., caused by medical examination or treatment) airway obstruction. It was the endotracheal tube we placed to correct her hypoxia and loss of protective airway reflexes that led to her airway compromise. And it represents an exception to the discussion of airway pressures above.

The patient's peak inspiratory pressures were elevated because of an obstructed airway, but her plateau pressures were also elevated because of the "simulated bronchospasm" caused by air return only through the eye of Murphy, through which the suction catheter no doubt passed to falsely indicate a lack of obstruction at the level of the endotracheal tube.

Conclusion

High airway pressures are indicative of a problem with the airway that's been placed, the ventilator being used to ventilate the patient, or the patient themselves.

Immediate assessment of each of those factors through a logical series of steps should help to identify the cause and allow for correction. And should that fail, we would suggest a simple turn of the endotracheal tube.